Science Bulletin 69 (2024) 872–875

Contents lists available at ScienceDirect

Science Bulletin

journal homepage: www.elsevier.com/locate/scib

Correspondence

DeepWMH: A deep learning tool for accurate white matter hyperintensity segmentation without requiring manual annotations for training

Chenghao Liu [a,1], Zhizheng Zhuo [b,1], Liying Qu [b], Ying Jin [b], Tiantian Hua [b], Jun Xu [c], Guirong Tan [b], Yuna Li [b], Yunyun Duan [b], Tingting Wang [c], Zaiqiang Zhang [c], Yanling Zhang [b], Rui Chen [b], Pinnan Yu [b], Peixin Zhang [b], Yulu Shi [c], Jianguo Zhang [d,e], Decai Tian [c,f,g], Runzhi Li [c,f], Xinghu Zhang [c], Fudong Shi [c,f,g], Yanli Wang [c,f], Jiwei Jiang [c,f], Aaron Carass [h], Yaou Liu [b,*], Chuyang Ye [a,*]

[a] *School of Integrated Circuits and Electronics, Beijing Institute of Technology, Beijing 100081, China*
[b] *Department of Radiology, Beijing Tiantan Hospital, Capital Medical University, Beijing 100070, China*
[c] *Department of Neurology, Beijing Tiantan Hospital, Capital Medical University, Beijing 100070, China*
[d] *Department of Neurosurgery, Beijing Tiantan Hospital, Capital Medical University, Beijing 100070, China*
[e] *Beijing Key Laboratory of Neurostimulation, Beijing 100070, China*
[f] *China National Clinical Research Center for Neurological Diseases, Beijing Tiantan Hospital, Beijing 100070, China*
[g] *Advanced Innovation Center for Human Brain Protection, Capital Medical University, Beijing 100070, China*
[h] *Department of Electrical and Computer Engineering, Johns Hopkins University, Baltimore 21205, USA*

White matter hyperintensities (WMHs) on fluid-attenuated inversion recovery (FLAIR) images are imaging features in various neurological diseases and essential markers for clinical impairment and disease progression. WMHs are associated with brain aging and pathological changes in the human brain, such as in Alzheimer's disease (AD) [1], Parkinson's disease (PD) [2], cerebral small vessel disease (SVD) [3], multiple sclerosis (MS) [4], neuromyelitis optica spectrum disorders (NMOSD) [5], and neuronal intranuclear inclusion disease (NIID) [6]. These WMH lesions correlate with behavioral and cognitive performance [7] and risk factors [8]. Efficient and reproducible quantitative analysis of WMH lesions can greatly benefit clinical practice and scientific research, and automated WMH segmentation enables such analyses. Therefore, the development of accurate automated WMH segmentation algorithms is highly desirable.

The earliest works on automated WMH segmentation use simple intensity thresholding strategies [9], but the accuracy on and applicability to different datasets can be poor due to the various appearances of WMH lesions. More advanced approaches, such as LST [10], analyze WMH morphology and use regression models or *k*-nearest neighbors for the segmentation. In recent years, the advancement in deep learning has benefited various image processing tasks [11], and deep learning techniques have also been used for WMH segmentation. In particular, convolutional neural networks (CNNs) are used for the task and have achieved state-of-the-art performance [12].

Despite the promising results achieved by CNN-based methods, the training of CNNs generally requires a large amount of annotated data. The annotations are made by radiologists with the relevant knowledge and expertise to ensure their reliability. The annotation of WMHs by an experienced rater on a 3D FLAIR image may cost six to eight hours, as WMHs can be small and randomly scattered throughout the whole brain. It is thus time-consuming and costly to annotate WMHs, which makes it impractical to curate a large-scale annotated WMH dataset for training CNN-based segmentation models. This greatly limits the use of CNN-based WMH segmentation in real-world applications. To lower the requirement for manual annotations, semi-supervised learning or transfer learning may be applied [13,14]. However, these methods still need expert-annotated training data and do not fully address the requirement for manual annotations.

Some works have attempted to apply the deep learning approach without any annotated training data [15], in which deep autoencoders are used. These works assume that an autoencoder trained to reconstruct normal-appearing images cannot capture the pathology in the images of patients, and WMHs can be identified using the residual image computed by subtracting the reconstructed image from the original image. Compared with manually annotating WMHs, the acquisition of normal-appearing images is much less expensive and more feasible. Although the idea of exploiting normal-appearing images provides a novel perspective that incorporates anatomical knowledge about normal tissue into network training, the use of the anatomical knowledge is not sufficiently effective in these works, as their segmentation accuracy is too low for practical use and can sometimes be even worse than simple intensity thresholding [9].

* Corresponding author.
E-mail addresses: yaouliu80@163.com (Y. Liu), chuyang.ye@bit.edu.cn (C. Ye).
[1] These authors contributed equally to this work.

https://doi.org/10.1016/j.scib.2024.01.034
2095-9273/© 2024 Science China Press. Published by Elsevier B.V. and Science China Press. All rights reserved.

To fully remove the need for manual WMH annotations for network training, we developed DeepWMH, an annotation-free, fully automated open-source tool for high-quality WMH segmentation based on deep learning. DeepWMH exploits the difference between normal-appearing and patient scans and combines it with the power of deep learning, which allows accurate segmentation of WMHs without manual annotations for model training. The pipeline of DeepWMH is shown in Fig. 1. DeepWMH comprises two separate phases, one for training and the other for inference. In the training phase, an unsupervised strategy is developed to train a CNN-based segmentation model without the need for any human intervention, where potential WMH locations are indicated based on reference normal-appearing scans, and they are used for model training with a training procedure that is robust to label noise. In the inference phase, the trained model performs end-to-end automated WMH segmentation. DeepWMH is fully automatic, and no hyperparameter tuning by the users is required. The detailed methodological description of DeepWMH is given in Method details in Supplementary Materials. DeepWMH can be used for both clinical application and scientific research. We provide the complete code for both training and inference at https://github.com/lchdl/DeepWMH, where DeepWMH is packaged as a standalone software program. A pretrained segmentation model is also provided so that it can be easily deployed.

DeepWMH was validated with 2203 scans from nine datasets acquired with 18 scanning protocols (for more details about the datasets, please refer to Dataset description and Fig. S1 (online) in Supplementary Materials) and compared with state-of-the-art annotation-free WMH segmentation methods (see Evaluation strategy and Table S1 online in Supplementary Materials). The Dice similarity coefficient, instance-level F1-score, and visual rating score (see Evaluation metrics in Supplementary Materials for the definition) were used as evaluation metrics. The data acquisition was approved by the institutional review board of Beijing Tiantan Hospital, Capital Medical University (No. KY 2021-028-03). Written informed consent was obtained from each participant according to the *Declaration of Helsinki*.

DeepWMH outperforms the competing methods by a large margin. Compared with best competing method (LST-LPA), DeepWMH improves the Dice similarity coefficient, instance-level F1-score, and visual rating score by 11%, 61%, and 38%, respectively. Moreover, the Dice coefficient and instance-level F1-score of DeepWMH are close to the inter-rater agreement (performance upper bound), where we have (DeepWMH vs. inter-rater agreement) 0.68 vs. 0.76 and 0.60 vs. 0.74 for the average Dice coefficient and instance-level F1-score, respectively. These results show the excellent performance of DeepWMH. DeepWMH was also compared with a fully supervised model, which consists of an nnU-Net [16] trained with annotated data. For internal testing where the training and test scans were from the same dataset, the fully supervised model achieved better performance than DeepWMH, and the gaps between them are on average 0.09 and 0.13 for the Dice similarity coefficient and instance-level F1-score, respectively. For external testing, where the test data was from a different dataset, because of the domain shift between the annotated training data and test data, the performance of the fully supervised model degraded drastically: on average it is worse than DeepWMH by large margins of 0.40 and 0.32 in terms of the Dice similarity coefficient and instance-level F1-score, respectively (see Table S2 online). More detailed analyses of the segmentation results are given in Detailed evaluation results and Figs. S2–S5 (online) in Supplementary Materials.

To summarize, we have developed an annotation-free deep learning tool DeepWMH for automated WMH segmentation.

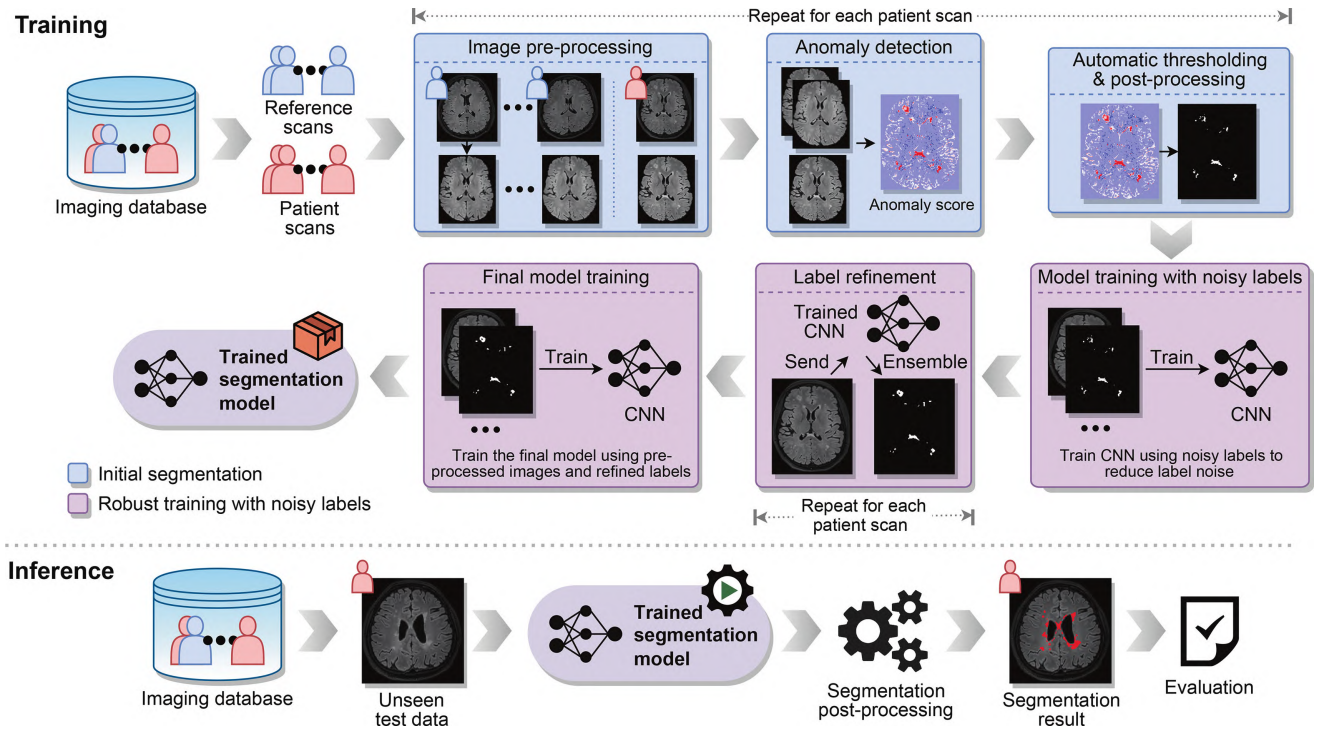

Fig. 1. An overview of DeepWMH for fully automated, high-quality WMH segmentation. DeepWMH comprises two phases, training and inference. The training phase is composed of two major steps: (1) an initial segmentation step that provides initial noisy WMH segmentation on patient scans (blue boxes); (2) model training with the initial noisy segmentation using a training procedure that is robust to label noise (purple boxes). In the inference phase, the trained CNN model performs WMH segmentation on unseen test images.

DeepWMH completely removes the requirement for manual WMH annotations for model training and thus greatly enhances the applicability of deep learning WMH segmentation in real-world scenarios. It exploits anatomical knowledge about normal brain tissue to indicate potential WMHs and integrates the indication with deep learning using a training strategy that is robust to label noise (see Figs. S6–S9 online). DeepWMH has achieved high-quality WMH segmentation and compares favorably with state-of-the-art annotation-free WMH segmentation approaches in terms of both quantitative evaluation and expert visual inspection. The performance of DeepWMH is stable across different datasets, in which data can vary due to different scanner models, types of brain disease, slice thicknesses, lesion locations, and lesion sizes (see Detailed evaluation results in Supplementary Materials). Based on the image data used in the experiments, for optimal DeepWMH performance, we recommend an in-plane image resolution of 1 mm × 1 mm and a slice thickness of 1 to 6 mm depending on the constraint of acquisition time. DeepWMH can be easily distributed, installed, and directly applied for both clinical application and scientific research. It may also inspire annotation-free segmentation of other types of brain lesions, where anatomical knowledge can be obtained with normal-appearing brain images and spatial normalization techniques.

Conflict of interest

The authors declare that they have no conflict of interest.

Acknowledgment

This work was supported by the Fundamental Research Funds for the Central Universities (2022CX1100), the Beijing Municipal Natural Science Foundation (JQ20035), the National Natural Science Foundation of China (81870958 and 81571631), and the Special Fund of the Pediatric Medical Coordinated Development Center of Beijing Hospitals Authority (XTYB201831).

Appendix A. Supplementary materials

Supplementary materials to this correspondences can be found online at https://doi.org/10.1016/j.scib.2024.01.034.

References

[1] Damulina A, Pirpamer L, Seiler S, et al. White matter hyperintensities in Alzheimer's disease: A lesion probability mapping study. J Alzheimer's Dis 2019;68:789–96.
[2] Bohnen NI, Albin RL. White matter lesions in Parkinson disease. Nat Rev Neurol 2011;7:229–36.
[3] van Norden AG, de Laat KF, Gons RA, et al. Causes and consequences of cerebral small vessel disease. The RUN DMC study: A prospective cohort study. Study rationale and protocol. BMC Neurol 2011;11:1–8.
[4] Filippi M, Rocca MA, De Stefano N, et al. Magnetic resonance techniques in multiple sclerosis: The present and the future. Arch Neurol 2011;68:1514–20.
[5] Chan KH, Tse C, Chung C, et al. Brain involvement in neuromyelitis optica spectrum disorders. Arch Neurol 2011;68:1432–2149.
[6] Sugiyama A, Sato N, Kimura Y, et al. MR imaging features of the cerebellum in adult-onset neuronal intranuclear inclusion disease: 8 cases. Am J Neuroradiol 2017;38:2100–4.
[7] Baezner H, Blahak C, Poggesi A, et al. Association of gait and balance disorders with age-related white matter changes: The LADIS study. Neurology 2008;70:935–42.
[8] Derraz I, Abdelrady M, Ahmed R, et al. Impact of white matter hyperintensity burden on outcome in large-vessel occlusion stroke. Radiology 2022;304:210419.
[9] Meissen F, Kaissis G, Rueckert D. Challenging current semi-supervised anomaly segmentation methods for brain MRI. arXiv preprint 2021:2109.06023.
[10] Schmidt P, Gaser C, Arsic M, et al. An automated tool for detection of FLAIR-hyperintense white-matter lesions in multiple sclerosis. Neuroimage 2012;59:3774–83.
[11] Minaee S, Boykov YY, Porikli F, et al. Image segmentation using deep learning: A survey. IEEE Trans Pattern Anal Mach Intell 2022;44:3523–42.
[12] Kuijf HJ, Biesbroek JM, De Bresser J, et al. Standardized assessment of automatic segmentation of white matter hyperintensities and results of the WMH segmentation challenge. IEEE Trans Med Imag 2019;38:2556–68.
[13] Baur C, Albarqouni S, Navab N. Semi-supervised deep learning for fully convolutional networks. In: International Conference on Medical Image Computing and Computer-Assisted Intervention. Cham: Springer; 2017. p. 311–9.
[14] Ghafoorian M, Mehrtash A, Kapur T, et al. Transfer learning for domain adaptation in MRI: application in brain lesion segmentation. In: International Conference on Medical Image Computing and Computer-Assisted Intervention. Cham: Springer; 2017. p. 516–24.
[15] Baur C, Denner S, Wiestler B, et al. Autoencoders for unsupervised anomaly segmentation in brain MR images: A comparative study. Med Image Anal 2021;69:101952.
[16] Isensee F, Jaeger PF, Kohl SA, et al. nnU-Net: A self-configuring method for deep learning-based biomedical image segmentation. Nat Methods 2021;18:203–11.

Chenghao Liu received his B.S. degree from Beijing Institute of Technology in 2019. He is currently a Ph.D. candidate at Beijing Institute of Technology, under the guidance of Prof. Chuyang Ye. His research focuses on medical image analysis using deep learning, especially in semi-supervised and unsupervised brain lesion segmentation.

Zhizheng Zhuo is an assistant professor working at Department of Radiology, Beijing Tiantan Hospital, Capital Medical University. He obtained doctoral degree from Capital Medical University in 2019, and had worked at Philips Health Care. His research focuses on MR imaging and subtyping major neurological diseases from MR imaging data.

Yaou Liu is the Director of Department of Radiology, Beijing Tiantan Hospital, Capital Medical University. He obtained two doctoral degrees from Capital Medical University in 2013 and VU University Amsterdam in 2017, and worked at the Neuroscience Center of the University of Melbourne, the University of Antwerp and the VU University Medical Center. His research focuses on the development and validation of imaging markers for major neurological diseases, especially in multiple sclerosis and neuro-oncology.

Chuyang Ye received his Ph.D. degree from the Johns Hopkins University in 2014. He then joined Institute of Automation, Chinese Academy of Sciences as an Assistant/Associate Professor (2015-2018). He is currently an Associate Professor at the School of Integrated Circuits and Electronics, Beijing Institute of Technology. His current research interest is medical image computing and its application to clinical and basic neuroscience.